

2024

Heart failure secondary to a snake bite. The intensivist's vision: case report

Andrés Alirio Restrepo Bastidas

Grupo Investigación de Medicina Crítica y Cuidados Intensivos GIMCCI. Universidad Tecnológica de Pereira, Pereira, Risaralda, Colombia.

Mateo Aguirre Flórez

Grupo Investigación de Medicina Crítica y Cuidados Intensivos GIMCCI. Universidad Tecnológica de Pereira, Pereira, Risaralda, Colombia.

Jaime Andrés Hoyos Muñoz

Grupo Investigación de Medicina Crítica y Cuidados Intensivos GIMCCI. Universidad Tecnológica de Pereira, Pereira, Risaralda, Colombia.

Melissa Gonzales Ramírez

Grupo Investigación de Medicina Crítica y Cuidados Intensivos GIMCCI. Universidad Tecnológica de Pereira, Pereira, Risaralda, Colombia.

David Ricardo Echeverry Piedrahita

Grupo Investigación de Medicina Crítica y Cuidados Intensivos GIMCCI. Universidad Tecnológica de Pereira, Pereira, Risaralda, Colombia.



Part of the [Health Information Technology Commons](#), [Medical Specialties Commons](#), and the [Public Health Commons](#)

Recommended Citation

Restrepo Bastidas, Andrés Alirio; Aguirre Flórez, Mateo; Hoyos Muñoz, Jaime Andrés; Gonzales Ramírez, Melissa; and Echeverry Piedrahita, David Ricardo (2024) "Heart failure secondary to a snake bite. The intensivist's vision: case report," *Revista de la Facultad de Medicina Humana*: Vol. 24: Iss. 1, Article 19.

DOI: <https://doi.org/10.25176/RFMH.v24i1.6099>






Available at: <https://inicib.urp.edu.pe/rfmh/vol24/iss1/19>

This Article is brought to you for free and open access by INICIB-URP. It has been accepted for inclusion in Revista de la Facultad de Medicina Humana by an authorized editor of INICIB-URP.



HEART FAILURE SECONDARY TO A SNAKE BITE. THE INTENSIVIST'S VISION: CASE REPORT

INSUFICIENCIA CARDÍACA SECUNDARIA A MORDEDURA DE SERPIENTE. LA VISIÓN DEL INTENSIVISTA:
REPORTE DE CASO

Andrés Alirio Restrepo Bastidas ¹, Mateo Aguirre Flórez ¹, Jaime Andrés Hoyos Muñoz ¹,
Melissa González Ramírez ¹, David Ricardo Echeverry Piedrahita ¹

ABSTRACT

Background: Ophidic accident is a neglected disease that affects tropical countries. Latin America is the second region after Africa, with the most cases worldwide. Local lesions accompany its clinical course up to systemic affectations such as renal, hematological, and neurological lesions. Cardiac complications are rare, especially in patients who do not have cardiovascular risk factors. There are reports of acute myocardial infarction, but there is little information about heart failure due to Bothrops spp. **Clinical case:** We present the case of a 25-year-old man without cardiovascular risk factors who was admitted to the intensive care unit and developed heart failure with cardiogenic shock and multi-organ failure secondary to a snake bite. **Conclusion:** Although the characteristic clinical course of a bothropic ophidian accident and its systemic manifestations are mainly related to coagulation abnormalities, there are cardiovascular complications within its clinical presentation that, although rare, if not detected promptly and not adequately managed, are associated with high morbidity and mortality.

Keywords: Bothrops spp; Cardiogenic shock; Colombia; Heart failure; Ophidic accident. (Source: MESH-NLM)

RESUMEN

Antecedentes: El accidente ofídico es una enfermedad desatendida que afecta a los países tropicales. América Latina es la segunda región después de África, con mayor número de casos a nivel mundial. Su curso clínico incluye lesiones locales hasta afectaciones sistémicas como lesiones renales, hematológicas y neurológicas. Las complicaciones cardíacas son raras, especialmente en pacientes que no tienen factores de riesgo cardiovascular. Hay reportes de infarto agudo de miocardio, pero existe poca información sobre la insuficiencia cardíaca debida a Bothrops spp. **Caso Clínico:** Presentamos el caso de un hombre de 25 años sin factores de riesgo cardiovascular que fue admitido en la unidad de cuidados intensivos y desarrolló insuficiencia cardíaca con choque cardiogénico y fallo multiorgánico secundario a una mordedura de serpiente. **Conclusiones:** Aunque el curso clínico característico de un accidente ofídico bothrópico y sus manifestaciones sistémicas están principalmente relacionadas con anomalías de la coagulación, hay complicaciones cardiovasculares dentro de su presentación clínica que, aunque raras, si no se detectan prontamente y no se manejan adecuadamente, están asociadas con alta morbilidad y mortalidad.

Palabras clave: Bothrops spp; Choque cardiogénico; Colombia; Insuficiencia cardíaca; Accidente ofídico. (Fuente: DeCS- BIREME)

¹ Grupo Investigación de Medicina Crítica y Cuidados Intensivos GIMCCI. Universidad Tecnológica de Pereira, Pereira, Risaralda, Colombia.

Cite as: Restrepo Bastidas AA, Aguirre Flórez M, Hoyos Muñoz JA, González Ramírez M, Echeverry Piedrahita DR. Heart failure secondary to a snake bite. the intensivist's vision: Case report. Rev Fac Med Hum. 2024;24(1):179-185. doi:10.25176/RFMH.v24i1.6099





INTRODUCTION

The existence of 3000 snake species has been estimated worldwide, of which 600 are poisonous and threaten public health⁽¹⁾. Therefore, in 2019, the World Health Organization (WHO) established the venomous snake bite as a neglected tropical disease⁽²⁾, with 5.4 million cases reported each year, 95 000 fatalities, and 300 000 patients with some degree of disability⁽²⁾. In Latin America, 70 000 cases per year are reported. Children, young agricultural workers and people from rural areas are among the most affected⁽²⁻⁴⁾.

intensive care unit (ICU) due to acute heart failure after being bitten by a *Bothrops* spp snake is presented.

CLINICAL CASE

A 25-year-old male, afro-descendant, agricultural worker, resident of a rural area, without known past diseases. He was admitted due to a *Bothrops* spp snake bite five hours earlier on the middle third of the posterior region of the right lower limb. Two punctiform lesions with mild but active bleeding were present. Edema, a diameter difference greater than four cm compared to the left lower limb, absent distal pulses, and sensitivity alterations were also present. A local expert identified the genus of the snake. Laboratory tests showed prolongation of coagulation times (aPTT: 54.8 sec. – Reference Range: 29.2 sec. PT: 47.7 sec. control: 12.9 sec. INR: 4.00), normal fibrinogen (>1200 mg/dL), creatinine phosphokinase (CPK) (7261.0 U/L) - elevated. Therefore, according to the National Institute of Health (NIH), the case was classified as severe, and the patient was treated according to the antivenom recommendations. In addition, doppler ultrasonography of the right lower extremity arteries and veins was performed, which showed signs of compartment syndrome (absence of color flows within the posterior tibial artery; posterior and anterior tibial veins). Therefore, fasciotomy of the lateral and medial compartments of the leg from knee to ankle was required, and muscle necrosis was observed during the procedure (figure 1).

CLINICAL CASE

Clinical findings range from local alterations such as erythema, pain, and bleeding⁽⁵⁾ to systemic complications like coagulopathies, necrosis, bacterial infections, nephropathies, and unusual complications like myocardial infarction and arrhythmias^(4,6), reports of more systemic severe alterations are rare⁽⁷⁾. Heart failure secondary to bothropic accident is infrequent; its origin is multifactorial due to hypercoagulability, direct cardiotoxicity, vasospasm, hypoperfusion due to hypovolemic shock and imbalance between procoagulant and anticoagulant elements; these factors can generate acute myocardial injury with heart failure and cardiogenic shock, events that have a significant impact on the prognosis of this pathology^(16,17,18). Therefore, appropriate knowledge of the treatment of venomous snake bites by medical staff is crucial to improving survival rates from this condition⁽⁸⁾. Consequently, the case of a 25-year-old male, without any cardiovascular risk factors, who was admitted to the

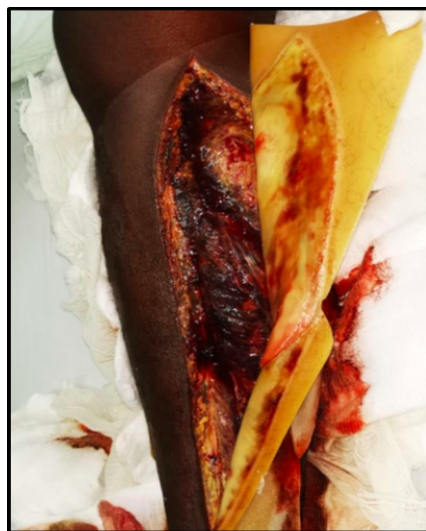

Figure 1. Lateral and medial fasciotomy was performed from the knee to the ankle and muscle necrosis was observed.



The patient was transferred to the ICU for postoperative care and required vasoactive support due to hemodynamic instability. The patient also showed severe and progressive changes in tissue perfusion parameters (SvcO₂: 57%, delta-pCO₂: 9, lactate: 9.9). An increase in vasoactive support dose and a second vasoactive drug was necessary. A transthoracic echocardiogram shows dilated cardiomyopathy with biventricular failure, left ventricular ejection fraction (LVEF): 25%; a tricuspid annular plane systolic excursion

(TAPSE) of 14 mm was performed. In addition, biomarker elevation (troponin I: 6.00 ng/ml - reference range: 0-0.120 ng/ml) indicated acute myocardial injury. Due to the echocardiographic findings and clinical condition, inotropic support with dobutamine was implemented. The patient progressed to acute type 1 respiratory failure, and advanced airway management with invasive mechanical ventilation was necessary (figure 2).

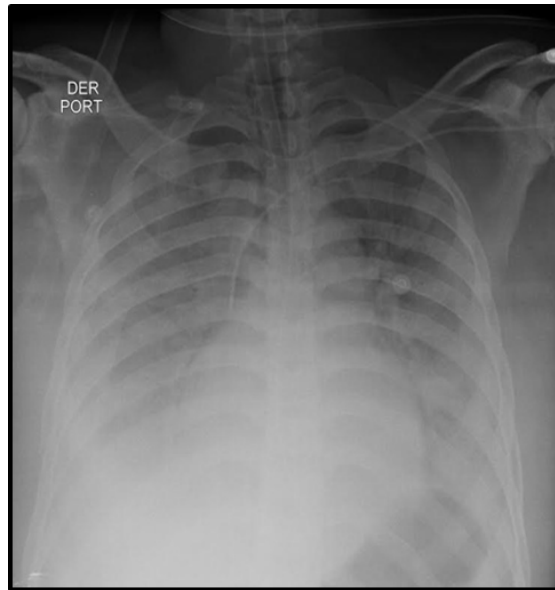


Figure 2. Chest X-ray with a pattern of acute pulmonary edema of cardiogenic origin.

The patient presented dobutamine intolerance with persistent tachycardia (heart rate > 130 per minute), so a change to levosimendan (dose 0.1 µg/kg/min for 24 hours) was needed. However, hyperlactatemia persisted, and high doses of vasoactive drugs were required. Invasive hemodynamic monitoring via pulmonary artery catheter (PAC) showed a hemodynamic pattern of cardiogenic shock (table 1). The patient progressed to multiple organ dysfunction syndrome by cardiovascular (cardiogenic shock), pulmonary (pulmonary edema), renal (acute kidney injury), hematological (coagulopathy) and liver involvement (transaminase elevation). Due to the

extension of muscle necrosis and the loss of limb viability, on the second day of hospitalization, a supracondylar amputation of the right inferior limb was carried out. A second inodilator was required (milrinone dose: 0.1 µg/kg/min). Afterward, the patient tolerated decreased vasoactive support and improved his tissue perfusion and kidney function indicators and reaching hemodynamic stability. On the fourth day of hospitalization, a control transthoracic echocardiogram showed LVEF recovery to 50%. In the following days, the inodilator decreased, orotracheal extubation was carried out, and the patient was transferred to the general ward on the fifth day of hospitalization.

Table 1. Invasive hemodynamic monitoring parameters with pulmonary artery catheter (PAC).

Hemodynamic variables	Values	Hemodynamic variables	Values
Cardiac Index	2.0 L/min/m ²	BSA	2024 m ²
SV	46.5 mL	SVI	23.0 ml/m ²
SRV	1259 Dinas/cm ⁵	SRVI	2549 Dinas*m ² /cm ⁵





PVR	120 Dinás/cm5	PVRI	243 Dinás*m2/cm5
LVSW	48.1 g*m	LVSWI	23.8 g*m/m2
RVSW	12.65 g*m	RVSWI	6.25 g*m/m2

BSA: body surface area, SV: stroke volume, SVI: systolic volume index, SVR: systemic vascular resistance, SVRI: systemic vascular resistance index, PVR: pulmonary vascular resistance, PVRI: pulmonary vascular resistance index, LVSW: left ventricular systolic work, LVSWI: left ventricular systolic work index, RVSW: Right Ventricular Systolic Work, RVSWI: right ventricular systolic work index.

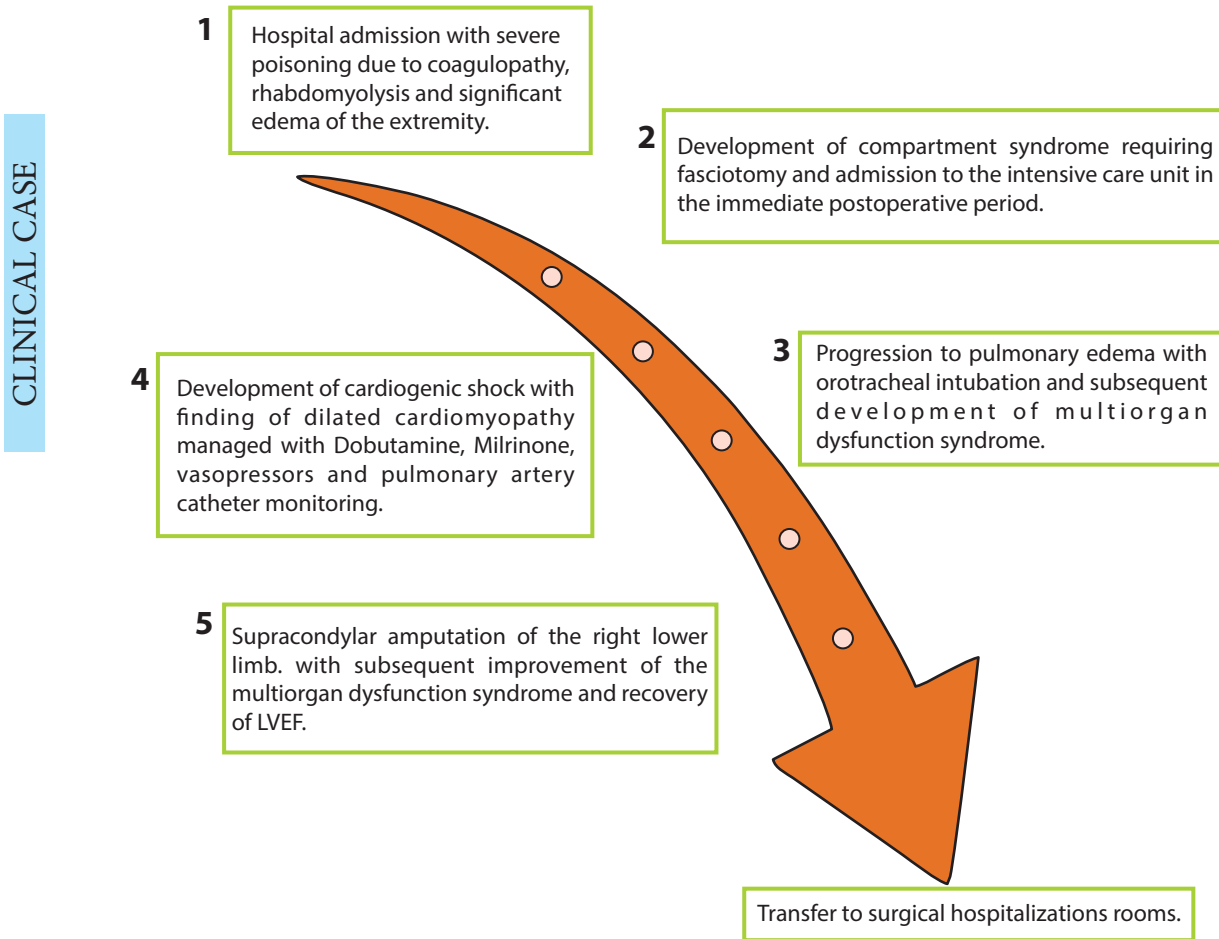


Figure 3. Timeline of relevant events.

DISCUSSION

Snakebite poisoning, specifically by the Bothrops snake, can have several pathophysiological effects on the body, what includes the risk of cardiogenic shock. Bothrops is a genus of venomous snakes found in Central and South America^(2,3). Here, we describe some of the basic pathophysiological mechanisms related to the development of cardiogenic shock after a Bothrops bite:

Hemorrhagic toxins: Bothrops venom contains

proteolytic enzymes and metalloproteinases that can cause damage to blood vessels and surrounding tissues. This vascular damage leads to localized bleeding and, in severe cases, a hemorrhagic syndrome that can affect multiple organs⁽⁴⁾.

Compartment syndrome: Tissue breakdown and localized edema can increase pressure in the affected muscle compartments. This increase in pressure can compromise local blood flow and contribute to shock development⁽⁵⁾.



Activation of the coagulation system: Bothrops venom can activate the coagulation system, which can result in a cascade of events leading to the formation of clots and consumption of clotting factors. This activation may contribute to microvascular thrombosis and tissue damage⁽⁶⁾.

Hypotension: Blood loss due to the hemorrhagic action of the venom, and possible decreased vascular resistance can lead to hypotension, a fundamental component of cardiogenic shock⁽⁶⁾.

Myotoxicity: Some Bothrops species can have myotoxic effects, what causes direct damage to muscle cells. The release of myoglobin and other damaged cellular products can contribute to acute renal failure, further aggravating the patient's hemodynamic condition⁽⁷⁾.

It is important to note that the clinical picture may vary, which depends on the specific species of Bothrops and the amount of venom inoculated. Immediate medical attention is crucial in venomous snake bites to counteract the effects of the venom and prevent serious complications such as cardiogenic shock. Depending on the patient's clinical manifestations, treatment may include antivenom administration, hemodynamic support measures, and other specific therapeutic approaches^(7,8). Venomous snake bite is a neglected tropical disease of great interest in public health^(1,2), and 5.4 million cases are reported yearly. It primarily affects tropical countries as Latin America, the second most affected territory after Africa⁽⁹⁾. Countries like Brazil report the highest cases, approximately 26 000 ophidian accidents yearly⁽³⁾. In Colombia, up to 4000 cases have been reported⁽¹⁰⁾, and it is the second country in Latin America with the highest number of cases^(3,10). Young men who work as farmers are the most affected^(4,9,10), and Bothrops spp is the most prevalent species and responsible for 70 to 90 % of cases in the region⁽¹⁰⁻¹²⁾.

Alterations caused by venomous snake bites are well known; local symptoms such as swelling, pain, bleeding, edema, and muscle necrosis associated with systemic involvement (hematological and renal mainly) are common^(3,4,13); on the other hand, different studies agree that cardiac complications are rare, especially among subjects without cardiovascular risk factors or known cardiac diseases⁽⁷⁾.

Four possible mechanisms have been proposed for the development of acute myocardial infarction in both humans and animals after an ophidian accident that generates heart failure: 1) vasospasm secondary to venom, 2) coronary thrombosis due to hypercoagulability, 3) direct cardiotoxicity generating myocarditis and 4) hypovolemic shock due to capillary leakage generation^(16,17). The venom of snakes of the Viperidae family contains activators of factor V and factor X, which generate changes in the procoagulant-anticoagulant balance. As a result, there is evidence of thrombosis of the coronary, cerebral, and pulmonary vasculature⁽¹⁸⁾. Generally, this type of event does not lead to thrombosis in humans since, in most cases, the venom injection is subcutaneous or intramuscular, leading to the development of coagulopathy, preferably by consumption^(19,20), but in the case of this patient, due to the large size of the snake, the volume of venom injected was very high with high penetration at intravascular level, what increases the risk of thrombosis.

In this case, it was defined as an acute cardiac injury due to troponin elevation with values greater than p99, associated with clinical and echocardiographic manifestations of myocardial ischemia, accord to the fourth definition of myocardial infarction⁽¹⁷⁾. Likewise, heart failure was documented due to the rapid progression of symptoms, a LVEF severely reduced, a Stevenson C hemodynamic profile, and signs of tissue hypoperfusion, what indicates cardiogenic shock confirmed by invasive hemodynamic monitoring with pulmonary artery catheter⁽¹⁸⁾. A study, performed in Brazil by Souza et al., identified risk factors for mortality in Brazilian Amazonia. They found that Bothrops spp caused most cases, and fatal complications were respiratory failure and kidney injury in 37 and 29.1 % of cases, respectively⁽¹²⁾. Only one patient with cardiac involvement was identified. These data might be correlated with those obtained by Suresh et al. after identifying the cause of death in a cohort of 533 patients in South India, where the most prevalent cause of death was renal failure in 22.9 % of cases, and several cases of death, caused by cardiac involvement, were reported⁽¹⁴⁾.

Likewise, a study by Sarmiento et al., that comprised 42 patients, showed that the most frequent complications were hematological and dermatological in 19.02 % of cases. However, it showed that three patients had





cardiac involvement and presents myocardial infarction⁽¹⁵⁾.

Limitations and strengths

The clinical case has several limitations, among which we highlight that heart failure secondary to a bothropic accident is a rare entity, so the literature available for its specific management is scarce, without forgetting that patients admitted to the ICU due to a bothropic accident have high mortality; on the other hand, in our context there is no availability of the adequate number of antidote vials, making its management more difficult. The main strengths are related to the timely detection, advanced hemodynamic monitoring, and

management of heart failure with secondary cardiogenic shock, as well as the different complications associated with the multi-organ dysfunction syndrome that the patient presented.

CONCLUSION

Although the characteristic clinical course of a bothropic ophidian accident and its systemic manifestations are mainly related to coagulation abnormalities, there are cardiovascular complications within its clinical presentation that, although rare, if not detected on time and not properly managed, are associated with high morbidity and mortality.

Conflicts of interest: No conflicts of interest were reported in the preparation of this work.

ACKNOWLEDGMENTS: To the intensive care unit staff of the Hospital Universitario San Jorge. Pereira, Risaralda, Colombia.

Received: December 04, 2023.

Approved: February 29, 2024.

Authorship contributions: Andres Restrepo-Bastidas: Study concept and design, acquisition, analysis, and interpretation of data, drafting of the manuscript, critical revision of the manuscript for important intellectual content, original material, and construction of figures. Mateo Aguirre-Flórez: Study concept and design, acquisition, analysis, and interpretation of data. English translation. Jaime Andrés Hoyos-Muñoz: Critical revision of the manuscript for important intellectual content and study supervision. Melissa González-Ramírez: Critical revision of the manuscript for important intellectual content and study supervision. David Echeverry-Piedrahita: Critical revision of the manuscript for important intellectual content and study supervision.

Financing: None.

Correspondence: Mateo Aguirre Flórez.

Address: Cra. 27 #10-02, Pereira, Risaralda, Colombia.

Email: maguirref96@utp.edu.co

REFERENCES

- Kasturiratne A, Wickremasinghe AR, de Silva N, Gunawardena NK, Pathmeswaran A, Premaratna R, et al. The Global Burden of Snakebite: A Literature Analysis and Modelling Based on Regional Estimates of Envenoming and Deaths. *PLOS Medicine*. 2008;5(11):e218. doi.org/10.1371/journal.pmed.0050218
- The L. Snake-bite envenoming: a priority neglected tropical disease. *Lancet* (London, England). 2017;390(10089):2. DOI: 10.1016/S0140-6736(17)31751-8
- Gutiérrez JM. Envenenamientos por mordeduras de serpientes en América Latina y el Caribe: Una visión integral de carácter regional. *Boletín de Malaria y Salud Ambiental*. 2011;51:1-16.
- Bhalla G, Mhaskar D, Agarwal A. A study of clinical profile of snake bite at a tertiary care centre. *Toxicol Int*. 2014;21(2):203-8. DOI: 10.4103/0971-6580.139811
- McGhee S, Finnegan A, Clochesy JM, Visovsky C. Effects of snake envenomation: a guide for emergency nurses. *Emergency nurse : the journal of the RCN Accident and Emergency Nursing Association*. 2015;22(9):24-9. DOI: 10.7748/en.22.9.24.e1406
- Virmani S, Bhat R, Rao R, Kapur R, Dsouza S. Paroxysmal Atrial Fibrillation due to Venomous Snake Bite. *J Clin Diagn Res*. 2017;11(6): OD01-OD2. DOI: 10.7860/JCDR/2017/27553.9971
- Chara K, Baccouche N, Turki O, Regaig K, Chaari A, Bahloul M, et al. A rare complication of viper envenomation: cardiac failure. A case report. *Medicine et sante tropicales*. 2017;27(1):52-5. DOI: 10.1684/mst.2016.0636
- Bhargava S, Kumari K, Sarin RK, Singh R. First-hand knowledge about snakes and snake-bite management: an urgent need. *Nagoya J Med Sci*. 2020;82(4):763-74. DOI: 10.18999/nagjms.82.4.763
- Maguiña-Vargas C, Chinchá-Lino O, Vilcapoma-Balbín P, Morante D. Actualización en clínica y terapia de mordedura de serpiente (ofidismo). *Revista Médica Herediana*. 2020;31:48-55. <http://dx.doi.org/10.20453/rmh.v31i1.3729>
- Cuellar Gordo LC, Amador Orozco B, Olivares Goenaga G, Borré Ortiz YM, Pinedo Otálvaro J. Comportamiento epidemiológico del accidente ofídico en el Departamento del Magdalena, Colombia (2009-2013). *Revista Ciencias de la Salud*. 2016;14:161-77. <http://dx.doi.org/10.12804/revsalud14.02.2016.02>
- Boadas J, Matos M, Bónoli S, Borges A, Vázquez-Suárez A, Serrano L, et al. Perfil eco-epidemiológico de los accidentes por ofidios en Monagas, Venezuela (2002-2006). *Boletín de Malaria y Salud Ambiental*. 2012;52:107-20.
- da Silva Souza A, de Almeida Gonçalves Sachett J, Alcântara JA, Freire M, Alecrim M, Lacerda M, et al. Snakebites as cause of deaths in the Western Brazilian Amazon: Why and who dies? Deaths from snakebites in the Amazon. *Toxicon : official journal of the International Society on Toxinology*. 2018;145:15-24. DOI: 10.1016/j.toxicon.2018.02.041
- Mitra S, Agarwal A, Shubhankar BU, Masih S, Krothapalli V, Lee BM, et al. Clinico-epidemiological Profile of Snake Bites over 6-year Period from a Rural Secondary Care Centre of Northern India: A Descriptive Study. *Toxicol Int*. 2015;22(1):77-82. doi: 10.4103/0971-6580.172263
- David S, Matathia S, Christopher S. Mortality predictors of snake bite envenomation in southern India—a ten-year retrospective audit of 533 patients. *J Med Toxicol*. 2012;8(2):118-23. DOI: 10.1007/s13181-011-0204-0
- Sarmiento K, Torres I, Guerra M, Ríos C, Zapata C, Suárez F. Epidemiological characterization of ophidian accidents in a Colombian tertiary referral hospital. Retrospective study 2004-2014. *Revista de la Facultad de Medicina*. 2018;66:153-8. <https://doi.org/10.15446/revfacmed.v66n2.61335>



16. Monteiro WM, Contreras-Bernal JC, Bisneto PF, Sachett J, Mendonça da Silva I, Lacerda M, et al. Bothrops atrox, the most important snake involved in human envenomings in the amazon: How venomics contributes to the knowledge of snake biology and clinical toxinology. *Toxicon: X*. 2020;6:100037. DOI: 10.1016/j.toxxc.2020.100037

17. Comentarios al consenso ESC 2018 sobre la cuarta definición universal del infarto de miocardio. *Revista Española de Cardiología*. 2019;72(1):10-5. DOI: 10.1016/j.recesp.2018.11.011

18. Kurmani S, Squire I. Acute Heart Failure: Definition, Classification and Epidemiology. *Curr Heart Fail Rep*. 2017;14(5):385-92. DOI: 10.1007/s11897-017-0351-y

