

2021

Near-fatal asthma as clinical manifestation in onset diabetic patient: Case report

César A. Chávez Paredes

Cristel Castillo Huerta

Alicia E. Chavez Cerna

Anthony F. Gutiérrez Salcedo

Katerine J. Hilario Vásquez

See next page for additional authors

Follow this and additional works at: <https://inicib.urp.edu.pe/rfmh>

Recommended Citation

Chávez Paredes, César A.; Castillo Huerta, Cristel; Chavez Cerna, Alicia E.; Gutiérrez Salcedo, Anthony F.; Hilario Vásquez, Katerine J.; Lam Cabanillas, Eduardo R.; and Rodríguez Benites, Arnold F. (2021) "Near-fatal asthma as clinical manifestation in onset diabetic patient: Case report," *Revista de la Facultad de Medicina Humana*: Vol. 22: Iss. 4, Article 25.

DOI: <https://doi.org/10.25176/RFMH.v22i4.4751>

Available at: <https://inicib.urp.edu.pe/rfmh/vol22/iss4/25>

This Article is brought to you for free and open access by INICIB-URP. It has been accepted for inclusion in Revista de la Facultad de Medicina Humana by an authorized editor of INICIB-URP.

Near-fatal asthma as clinical manifestation in onset diabetic patient: Case report

Authors

César A. Chávez Paredes, Cristel Castillo Huerta, Alicia E. Chavez Cerna, Anthony F. Gutiérrez Salcedo, Katerine J. Hilario Vásquez, Eduardo R. Lam Cabanillas, and Arnold F. Rodríguez Benites



NEAR-FATAL ASTHMA AS CLINICAL MANIFESTATION IN ONSET DIABETIC PATIENT: CASE REPORT

ASMA CASI FATAL COMO MANIFESTACIÓN CLÍNICA EN PACIENTE DIABÉTICA
DEBUT: REPORTE DE CASO

César A. Chávez-Paredes^{1,a}, Cristel Castillo-Huerta^{1,a}, Alicia E. Chavez-Cerna^{1,a}, Franz Gutierrez-Salcedo^{1,a},
Katerine Hilario^{1,a}, Eduardo Lam-Cabanillas^{1,a}, Arnold Frank Rodríguez-Benites^{1,2,3,b,c}

ABSTRACT

Introduction: Near-fatal asthma (NFA) is defined as the most severe form of asthma characterized by a refractory asthma attack with an arterial carbon dioxide tension (PaCO₂) greater than 45 mmHg and altered consciousness, requiring mechanical ventilation. **Clinical Case:** We reported the case of 40-year-old female patient, obese and asthmatic with irregular treatment who presented dyspnea accompanied by severe oppressive chest pain and loss of consciousness, with generalized cyanosis and severe shortness of breath, for which she underwent emergency endotracheal intubation and mechanical ventilation. Laboratory tests show decompensated respiratory acidosis, glycemia of 258 mg / dl and HbA1C of 7.94%; her diagnosing diabetes mellitus (DM). The presentation of NFA is rare and as a clinical manifestation in an obese patient with onset diabetic has never been reported in Peru; therefore, asthmatic patients with obesity and DM should be monitored due to the susceptibility to develop NFA.

Keywords: Asthma; Diabetes mellitus; Mechanical ventilation. (Source: MeSH NLM)

RESUMEN

Introducción: El asma casi fatal (ACF) se define como la forma más severa de asma que se caracteriza por una crisis asmática refractaria con una presión parcial de dióxido de carbono (PaCO₂) mayor a 45 mmHg y alteración de la conciencia que requiere ventilación mecánica. **Caso clínico:** Presentamos a una paciente de 40 años, obesa y asmática con tratamiento irregular que acude por disnea acompañada de dolor torácico tipo opresivo de intensidad severa y pérdida de la conciencia, con cianosis generalizada y dificultad intensa para respirar por lo que se le realiza intubación endotraqueal de emergencia y ventilación mecánica. En los exámenes de laboratorio se encuentra acidosis respiratoria descompensada, glicemia de 258 mg/dl y HbA1C de 7,94%; diagnosticándole diabetes mellitus (DM). La presentación del ACF es poco frecuente y como manifestación clínica en una paciente obesa con DM debut nunca se ha reportado en el Perú; por tal motivo, se debe vigilar a los pacientes asmáticos con obesidad y DM debido a la susceptibilidad a desarrollar un ACF.

Palabras clave: Asma; Diabetes mellitus; Ventilación mecánica. (Fuente: DeCS BIREME)

¹ Facultad de medicina. Universidad Nacional de Trujillo. Trujillo, Perú.

² Instituto Regional de Enfermedades Neoplásicas. Trujillo, Perú.

³ Hospital Belén de Trujillo. Trujillo, Perú.

^a Medical student.

^b Physician, internal medicine.

^c Master in Human Medicine.

Cite as: Chávez-Paredes CA, Castillo-Huerta C, Chavez-Cerna AE, Gutierrez-Salcedo F, Hilario K, Lam-Cabanillas E, Rodríguez-Benites AF. Near-fatal asthma as clinical manifestation in onset diabetic patient: Case report. Rev Fac Med Hum. 2022;22(4):888-892.

[doi 10.25176/RFMH.v22i4.4751](https://doi.org/10.25176/RFMH.v22i4.4751)

Journal home page: <http://revistas.urp.edu.pe/index.php/RFMH>

Article published by the Magazine of the Faculty of Human Medicine of the Ricardo Palma University. It is an open access article, distributed under the terms of the Creative Commons License: Creative Commons Attribution 4.0 International, CC BY 4.0 (<https://creativecommons.org/licenses/by/4.0/>), that allows non-commercial use, distribution and reproduction in any medium, provided that the original work is duly cited. For commercial use, please contact revista.medicina@urp.edu.pe





INTRODUCTION

Near-fatal asthma (NFA) is an inflammatory disease of the respiratory system in which a conventional therapeutic approach has failed, it is characterized by a refractory asthmatic crisis with a partial pressure of carbon dioxide (PaCO₂) greater than 45 mmHg, consciousness level alteration, and mechanical ventilation requirement^(1,2). NFA affects 5 out of 100,000 asthma patients per year globally⁽¹⁾. In Peru, there have been no studies at the national level on the clinical-epidemiological characteristics of asthmatic patients who arrive at emergency areas⁽³⁾. However, a study conducted at the Daniel Alcides Carrión National Hospital found that the annual incidence of patients who met the criteria for near-fatal asthma was 4 per 1,000 hospitalized patients diagnosed with asthma⁽⁴⁾.

Several risk factors for death related to asthma have been identified, such as a history of previous intubation, ICU stay, multiple emergency visits during the previous year, abuse of beta-agonist drugs, respiratory tract infections, sensitivity to aeroallergens, age, respiratory tract infections, systemic dependence on glucocorticoids⁽⁵⁻⁷⁾. Similarly, diabetes mellitus is also a risk factor with great relevance in recent years due to its high incidence worldwide and common comorbidity in asthmatic patients^(8,9).

The mechanisms that explain the exacerbation of asthma in diabetic patients are not yet fully elucidated, it is hypothesized that low-grade systemic inflammation and hyperglycemia are key points for their understanding⁽⁹⁻¹¹⁾. Although the coexistence of asthma and diabetes mellitus in the same patient is frequent, there is little information worldwide and none in Peru on near-fatal asthma as a clinical manifestation in diabetic patients, therefore, the aim of this work is to describe the clinical picture in a case of near-fatal asthma as a clinical manifestation in a debut diabetic patient for its recognition in the emergency area and to carry out an adequate therapeutic approach.

DESCRIPTION OF THE CLINICAL CASE

A 40-year-old female patient with incomplete high school, from Moche who works in outpatient commerce, has had asthma for 10 years with irregular

treatment, with no family history of the disease. In laboratory tests, he has an arterial blood gas study, he also has type I obesity (BMI: 30) and uncontrolled arterial hypertension. She has history of COVID-19 a year ago and a dust allergy; In addition, her mother was diagnosed with prediabetes approximately 8 years ago.

One week before going to the emergency room and being hospitalized, she presented dyspnea with an insidious onset and a progressive course, generally in the afternoons and at night, which limits her ability to carry out her daily activities and worsens due to exposure to humidity, cold, and the realization of higher efforts. During that week, she presented 3-4 shortness of breath crises a day and went to a medical center near his home to have nebulizations performed.

One day before admission, she suffered crises of acute dyspnea with little effort that did not improve with inhaled salbutamol. In the emergency service, she was admitted with dyspnea accompanied by signs of respiratory distress, poor general condition and an oxygen saturation of 85%, oppressive retrosternal chest pain of severe intensity and generalized cyanosis, disorder of consciousness, snoring in the middle and bases of both hemithorax with a predominance of right hemithorax, rhythmic and regular heart sounds. Information on emergency baseline pulmonary function tests could not be obtained.

A few minutes after her emergency stay, she presented a sudden loss of consciousness where a respiratory arrest was identified, for which emergency endotracheal intubation was performed, she was transferred to perform a chest X-ray (Fig 1) and then received support with mechanical ventilation plus sedoanalgesia. A RT-PCR test for SARS-CoV-2 was requested with a negative result and laboratory tests (Table 1). Arterial blood gas analysis (AGA) revealed decompensated respiratory acidosis and hyperglycemia; Furthermore, a high value was obtained in the glycosylated hemoglobin test, for which she was diagnosed with type 2 diabetes mellitus (DM2), decompensated by hyperglycemia. The patient does not present with complications of ketoacidosis or hyperosmolar state, an interconsultation with the ICU was carried out for management in that service; however, it did not have beds available.



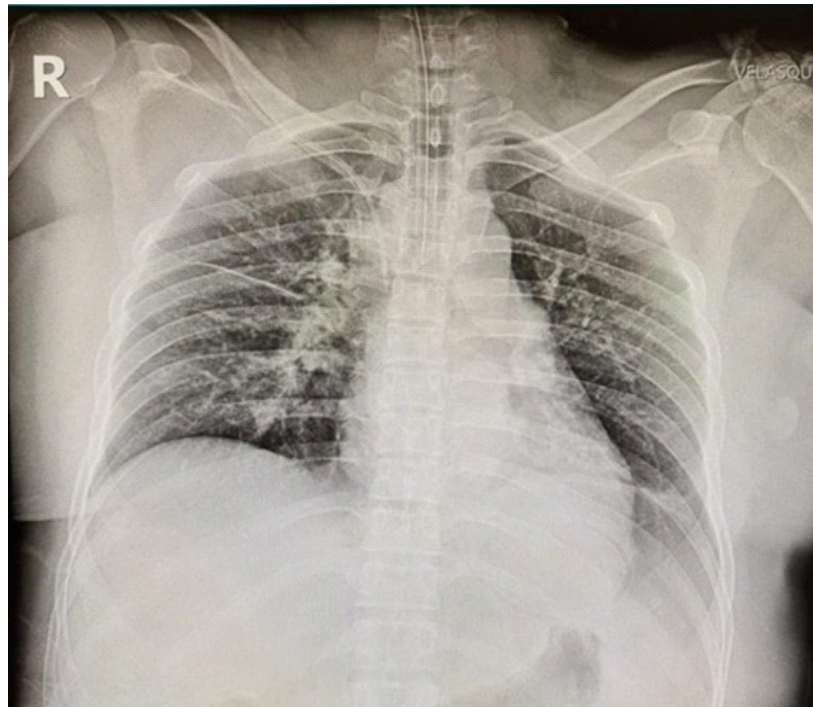


Figure 1. Simple anteroposterior projection chest X-ray. Interstitial congestion pattern (Kerley lines), prominence of the pulmonary arterial arch, accentuated bronchovascular pattern, presence of an endotracheal tube with a distal tip projecting close to the carina and a right-access central venous catheter with a distal tip projecting into the superior vena cava.

Table 1. Laboratory tests on admission.

PARAMETER	RESULT	NORMAL VALUES
pH	7.29	7,35-7,45
PCO ₂ (mmHg)	49.8	35-45
PO ₂ (mmHg)	54.4	80-100
HCO ₃ (mEq)	24.2	20-24
SatO ₂ (%)	89.4	95-100
Glu (mg/dl)	258	70-99
HbA _{1C} (%)	7.94	<5,7

The next day, the patient remains in support with mechanical ventilation and sedoanalgesia; Physical examination shows absence of breath sounds (silent lung). Subsequently, he received inhalations of bronchodilators by MDI (Metered Dose Inhaler) and corticosteroid therapy. Magnesium sulfate was used as a complement to first-line therapy, to which it did not present a favorable response, so ketamine, norepinephrine, insulin infusion therapy, and antibiotic therapy (ceftriaxone, clindamycin) were indicated due

to the suspicion of a bacterial infectious process. over aggregated.

In the subsequent days, during his stay on mechanical ventilator support under the aforementioned conditions, she presented an unfavorable evolution with hemodynamic instability, laboratory tests (Table 2), and high suspicion of pneumonia associated with mechanical ventilation, for which reason the rotation of antibiotics to Carbapenems (Meropenem). After 4 days



with the change of antibiotic therapy, she presents a slight ventilatory and hemodynamic improvement, a tracheostomy was performed, after which she was weaned and taken off the mechanical ventilator after 14

days. Later, she is transferred to hospitalization to complete treatment, and from where she is discharged after 20 days.

Table 2. Laboratory tests during evolution in relation to treatment.

Exams	Evolution throughout days				
	3 hours later	Day 2	Day 3	Day 4	Day 5
FiO2 (%)	100%	80%	45%	45%	21%
pH	7.01	6.98	7.28	7.07	7.44
pCO ₂ (mmHg)	145.9	158	60.5	107.9	38.7
pO ₂ (mmHg)	208.2	79.4	88.2	90.8	77.8
HCO ₃ (mEq)	37.4	38	29.3	31.9	26.6
SatO ₂ (%)	99.0	83.7	95.2	91.4	95.9
Gluc(mg/dl)	264	252	222	185	205
PaFiO ₂	208.2	158.8	220.4	201.9	311
K ⁺ (mEq/L)	5.6	6.69	4.76	6.34	3.42
BUN (mg/dl)	18	22	27	32	14

DISCUSSION

Near-fatal asthma defines a subset of patients with asthma who are at increased risk of death from their disease⁽¹²⁾. Studies show that deaths from asthma attacks typically occur in patients with poorly controlled asthma whose condition gradually deteriorates over days or weeks before the fatal or near-fatal episode of asthma occurs⁽¹³⁾. The signs and symptoms that were evidenced in the patient were decreased consciousness level, respiratory distress, cyanosis, auscultatory silence, SatO₂ of 89.4% (<90%), PaO₂ of 54.4 mmHg (<60 mmHg) and PaCO₂ of 49.8 mmHg (>45mmHg), which are consistent with the clinical manifestations of NFA, which could have led to the development of respiratory arrest^(1,6,12).

As usual management of NFA, immediate ventilatory support is given to preserve adequate oxygenation, reduce dynamic hyperinflation and reduce probable hypercapnia (confirmed in the AGA); and subsequently administer nebulized B2-agonists, systemic corticosteroids, theophylline, ketamine, or epinephrine, which relieve airflow with reduction of airway obstruction and mucus; depending on the situation^(6,14). In this case, the patient was refractory to salbutamol nebulization before admission to the

emergency room; After endotracheal intubation and mechanical ventilation, there was no favorable response to magnesium sulfate, so ketamine, norepinephrine, and vasopressors were indicated, described as part of non-conventional therapy⁽⁶⁾.

Several risk factors were identified in this patient, such as low socioeconomic status, irregular treatment of asthma, difficulty in perceiving the severity of her symptoms, and ignorance of the condition of DM2 by the patient and her relatives; which together led to their high risk of death.

Among these factors, DM2 stands out due to its association with worsening asthma control, increasing the chances of exacerbations, complications and hospitalizations^(10,11). The hypothesis of its association is based on low-grade systemic inflammation, characterized by high levels of inflammatory markers such as IL-6 and TNF-alpha that favor the differentiation of Th2 cells into Th17 and the production of high levels of IL-17 that are seen in severe asthma; as well as in obese people and those with DM2, conditions present in this patient^(10,15,16). Besides, hyperglycemia generates advanced glycation end products that can affect microvascular structures such as the





alveolar capillary network in the lung; which reduces lung function and decreases lung capacity⁽¹⁰⁾.

Additionally, research has found a decreased risk of hospitalizations for asthma in diabetic patients who have regular treatment with metformin^(16,17), which contributes to the explanation of the almost fatal asthma in this case, since being a debut diabetic patient did not have a treatment before admission.

Despite the precipitating factors for NFA already mentioned and according to the study conducted by Sandrock C, et al⁽¹⁸⁾, viral infections represented 59% of the patients, with rhinovirus, particularly human rhinovirus-C, being the Most common causative agent detected 5 days prior to asthma exacerbation. Other viruses that cause this complication are also mentioned, such as respiratory syncytial virus (RSV)

type A and B, as well as influenza A, which seem to be the most frequent and recurrent threats. In this case, the viral infection by rhinovirus could explain the manifestation of almost fatal asthma in the patient; even more, having diabetes mellitus which generates immunosuppression. However, a severe bacterial infection that is not secondary to a viral infection would be unlikely to cause near-fatal asthma.

The patient did not show symptoms of viral infection days before emergency admission; In addition, no diagnostic tests were performed to rule out the presence of said infection.

In conclusion, the presentation of NFA is rare and has not been reported in Peru as a clinical manifestation in an obese patient with debut DM; for this reason, asthmatic patients with obesity and DM should be monitored due to the susceptibility to developing an NFA.

Authorship contributions: The authors contributed to the genesis of the idea and creation of the manuscript.

Conflicts of interest: Authors had declared to have no conflicts of interest.

Funding sources: Self financed.

Received: february 04, 2022

Approved: july 16, 2022

Correspondence: César Augusto Chávez Paredes.

Address: Hierro Mz "Q" It 35. Urb. San Isidro, Trujillo, Perú.

Telephone number: +51 927692687

E-mail: cachavez@unitru.edu.pe

REFERENCES

- Mora C, Urbina Medina, Urbina H, Lobo P, Barreto O. Asma casi fatal. Archivos Venezolanos de Puericultura y Pediatría [Internet]. 2010 [citado el 20 de noviembre del 2021];73(3):47-54. Disponible en: <https://www.redalyc.org/pdf/3679/367936952009.pdf>
- Doshi V, Shenoy S, Ganesh A, Lankala S, Henkle J. Near Fatal Asthma in an Inner City Population. Am J Ther [Internet]. 2016 [citado el 20 de noviembre del 2021]; 23(6):1375-1380. DOI: 10.1097/MJT.0000000000000152.
- Cachay J. Evaluación clínico-flujométrica en exacerbaciones agudas de asma bronquial, tratados con Fenoterol, en un Servicio de Emergencia, en adultos [Tesis de Especialidad]. Perú: Universidad Nacional Mayor de San Marcos; 2015. Disponible en: https://cybertesis.unmsm.edu.pe/bitstream/handle/20.500.12672/13500/Cachay_Diaz_Jose_Ramiro_2015.pdf?sequence=1
- Sánchez K. Asma casi fatal en el Hospital Nacional Daniel Alcides Carrión entre febrero 1998 a febrero 2008. Interciencia [Internet]. 2008 [citado el 20 de noviembre del 2021];2(3):10-19. Disponible en: https://www.clinicainternacional.com.pe/pdf/revista-interciencia/4/Articulo_Orignal2.pdf
- Serrano-Pariente J, Plaza V. Near-fatal asthma: A heterogeneous clinical entity. Curr Opin Allergy Clin Immunol [Internet]. 2017 [citado el 20 de noviembre del 2021];17(1):28-35. DOI: 10.1097/ACI.0000000000000333
- D'Amato G, Vitale C, Lanza M, Sanduzzi A, Molino A, Mormile M, et al. Near fatal asthma: Treatment and prevention. Eur Ann Allergy Clin Immunol [Internet]. 2016 [citado el 20 de noviembre del 2021];48:116-22. Disponible en: <https://mrmjournal.biomedcentral.com/articles/10.1186/s40248-016-0073-0>
- D'Amato G, Vitale C, Molino A, Stanzola A, Sanduzzi A, Vatrella A, et al. Asthma-related deaths. Multidiscip Respir Med [Internet]. 2016 [citado el 20 de noviembre del 2021];11(1):1-5. DOI: 10.1186/s40248-016-0073-0.
- Chang Y, Ko H, Lu M, Chpu C, Su K, Hsu C, et al. Independent risk factors for death in patients admitted for asthma exacerbation in Taiwan. Care Respir Med [Internet]. 2020 [citado el 20 de noviembre del 2021];30(7). DOI: 10.1038/s41533-020-0164-4.
- Kosmalski M, Rozycka-Kosmalska M, Witusik A, Pietras T. The coincidence of diabetes mellitus and asthma, their probable causal relationships and therapeutic opportunities. Adv Respir Med [Internet]. 2020 [citado el 20 de noviembre del 2021];88:590-598. DOI: 10.5603/ARM.a20.0168.
- Marques R, Dos Santos M, Carvalho A, Marques L, Souza-Machado C. Association between Asthma and Type 2 Diabetes Mellitus-A Literature Review. Can Respir J [Internet]. 2021 [citado el 20 de noviembre del 2021];Article ID 8830439. DOI: 10.1155/2021/8830439.
- Khateeb J, Fuchs E, Khamaisi M. Diabetes and Lung Disease: An Underestimated Relationship. Rev Diabet Stud [Internet]. 2019 [citado el 20 de noviembre del 2021];15. DOI: 10.1900/RDS.2019.15.1
- Sabin B, Greenberger P. Potentially (near) fatal asthma. Allergy Asthma Proc [Internet]. 2012 [citado el 20 de noviembre del 2021];33(Supl 1): S44-S46. DOI: doi.org/10.2500/aap.2012.33.3546
- Restrepo R, Peters J. Near-fatal asthma: recognition and management. Curr Opin Pulm Med [Internet]. 2008 [citado el 7 de diciembre del 2021];14:13-23. DOI: [10.1097/MCP.0b013e3282f1982d](https://doi.org/10.1097/MCP.0b013e3282f1982d)
- Bermeo L, Velasco D. Guía para el tratamiento de la crisis asmática. Arc Med Urg Méx [Internet]. 2013 [citado el 7 de diciembre del 2021];5(2):60-69. Disponible en: <https://www.mediagraphic.com/pdfs/urgencia/aur-2013/aur132c.pdf>
- Carpaji O, van den Berge M. The asthma-obesity relationship: underlying mechanisms and treatment implications. Curr Opin Pulm Med [Internet]. 2018 [citado el 7 de diciembre del 2021];24:42-49. DOI: 10.1097/MCP.0000000000000446
- Wu T. Diabetes, insulin resistance, and asthma: a review of potential links. Curr Opin Pulm Med [Internet]. 2021 [citado el 7 de diciembre del 2021];27:29-36. DOI: 10.1097/MCP.0000000000000738.
- Wn L, Zhong W, Chai Y, Zhong Q, Gao J, Guan L, et al. Association of Metformin Use with Asthma Exacerbation in Patients with Concurrent Asthma and Diabetes: A Systematic Review and Meta-Analysis of Observational Studies. Can Respir J [Internet]. 2020 [citado el 7 de diciembre del 2021];Article ID 9705604. DOI: 10.1155/2020/9705604.
- Sandrock C, Norris A. Infection in Severe Asthma Exacerbations and Critical Asthma Syndrome. Clin Rev Allergy Immunol [Internet]. 2015 [citado el 7 de diciembre del 2021];48(1):104-13. DOI: 10.1007/s12016-014-8435-x

