

2021

Incidental Ectopic pancreas in gallbladder: a case report

Pedro L. Zamora Gonzales

Carmen E. Yagui Uku

José Somocurcio Peralta

Ronald A. Goicochea

Hospital Nacional Edgardo Rebagliati Martins, Lima-Perú, ronald_goicochea@hotmail.com

Follow this and additional works at: <https://inicib.urp.edu.pe/rfmh>

Recommended Citation

Zamora Gonzales, Pedro L.; Yagui Uku, Carmen E.; Somocurcio Peralta, José; and Goicochea, Ronald A. (2021) "Incidental Ectopic pancreas in gallbladder: a case report," *Revista de la Facultad de Medicina Humana*: Vol. 22: Iss. 2, Article 25.

DOI: <https://doi.org/10.25176/RFMH.v22i2.4397>

Available at: <https://inicib.urp.edu.pe/rfmh/vol22/iss2/25>

This Article is brought to you for free and open access by INICIB-URP. It has been accepted for inclusion in Revista de la Facultad de Medicina Humana by an authorized editor of INICIB-URP.



INCIDENTAL ECTOPIC PANCREAS IN THE GALLBLADDER CASE REPORT

INCIDENTAL ECTOPIC PANCREAS IN GALLBLADDER: A CASE REPORT

Zamora-G Pedro^{1,a}, Yagui-U Carmen^{2,b}, Somocurcio-P José^{1,b},
Goicochea-A Ronald^{1,c}

ABSTRACT

Ectopic pancreas is an unusual finding, with an incidence below 0,5% of all reports worldwide. We report the case of a 26-year-old woman who went to the emergency (department) for abdominal pain and underwent laparoscopic cholecystectomy. The pathology report described pancreatic ectopic tissue in the gallbladder wall. This finding must be thoroughly evaluated because this tissue can suffer diseases such as pancreatitis, cystic (tumors) and malignant degeneration, and should be (considered) in the context of gallbladder (polyps) with digestive (symptomatology).

Keywords: Gallbladder; Pancreas; Ectopic tissue; Incidental findings. (Source: MeSH NLM)

RESUMEN

El páncreas ectópico en vesícula biliar es un hallazgo poco frecuente, con una incidencia menor a 0,5% de los casos descritos en la literatura. Reportamos el caso de una mujer de 26 años que acude a emergencia por dolor abdominal quien fue sometida a una colecistectomía laparoscópica. El reporte anatomopatológico describió tejido pancreático ectópico en la pared de la vesícula biliar. Este hallazgo debe ser evaluado minuciosamente debido a la susceptibilidad del tejido pancreático a patologías como pancreatitis, lesiones quísticas y degeneración maligna, y debe ser considerado en el contexto de un pólipo vesicular asociado a sintomatología digestiva.

Palabras claves: Vesícula biliar; Páncreas; Tejido ectópico; Hallazgo incidental. (Fuente: DeCS BIREME).

¹ Hospital Nacional Edgardo Rebagliati Martins, Lima, Perú.

² Hospital Nacional Daniel A. Carrión, Callao, Perú.

^a Mg, MD Especialista en Cirugía General.

^b Mg, MD Especialista en Patología Clínica.

^c MD, Especialista en Cirugía general

Cite as: Zamora G Pedro, Yagui U Carmen, Somocurcio P José, Goicochea A Ronald. Incidental Ectopic Pancreas in the Gallbladder Case Report. Rev. Fac. Med. Hum. 2022; 22(2):507-510. DOI: 10.25176/RFMH.v22i2.4397

Journal home page: <http://revistas.urp.edu.pe/index.php/RFMH>

Article published by the Magazine of the Faculty of Human Medicine of the Ricardo Palma University. It is an open access article, distributed under the terms of the Creative Commons License: Creative Commons Attribution 4.0 International, CC BY 4.0 (<https://creativecommons.org/licenses/by/4.0/>), that allows non-commercial use, distribution and reproduction in any medium, provided that the original work is duly cited. For commercial use, please contact revista.medicina@urp.pe





INTRODUCTION

Pancreatic ectopia is the finding of normal pancreatic tissue in an abnormal location⁽¹⁾. The most common presentation sites are the stomach, duodenum, and small intestine^(1,3), with gallbladder location being infrequent^(2,3).

The incidence of pancreatic tissue in the gallbladder is usually less than 0,5% reported in all cases of the ectopic pancreas⁽³⁾. These cases are usually asymptomatic^(1,4,5); however, they may be associated with abdominal pain, nausea, and anorexia⁽³⁾. This ectopic pancreatic tissue can degenerate into metaplasia or malignant neoplasia, which is why its diagnosis and treatment are important⁽¹⁾. We report the incidental finding of ectopic pancreatic tissue in the fundus of a gallbladder in a patient operated on for gallbladder polyp associated with symptoms.

CASE REPORT

A 26-year-old female patient with no relevant medical history attends the emergency room of a local clinic for evaluation of abdominal pain associated with vomiting and liquid stools. This condition began two days ago. She is evaluated in an emergency by the doctor on duty who ordered auxiliary tests (blood count and electrolytes); the results were leukocytes at 8,12 103/uL hemoglobin 12,7g/dL platelets 254 103/uL Na⁺ 137,6 mmol/L K⁺ 3,82 mmol/L Cl⁻ 105 mmol/L; the patient was discharged with proton pump inhibitors and antispasmodics.

The patient was readmitted to the emergency department two days later due to abdominal pain associated with general malaise and nausea. The general surgeon evaluates the patient and indicates additional tests (blood count and urine test) and

abdominal ultrasound. Laboratory tests remained within normal values, and abdominal ultrasound only incidentally revealed a 7 mm polyp in the gallbladder. The patient was discharged with an indication for evaluation in the general surgery outpatient clinic and possible scheduling for elective surgery (cholecystectomy). Five days later, the patient was readmitted for the third time to the emergency department due to abdominal pain that radiated to the right dorsal region, associated with nausea, vomiting, and a sensation of temperature rise. The general surgeon reassessed the patient and requested another abdominal ultrasound for acute cholecystitis.

Ultrasound does not show inflammatory gallbladder changes; however, a 7mm gallbladder polyp is described; therefore, she is discharged with an indication of evaluation by external consultation. The patient is evaluated by a general surgery outpatient clinic and scheduled for elective surgery (laparoscopic cholecystectomy), which is performed 10 days after the first emergency admission. The surgical procedure (laparoscopic cholecystectomy) was performed without complications. The patient evolved favorably and was discharged on the second postoperative. The patient is evaluated by an outpatient clinic 10 days after discharge, without presenting any symptoms.

The anatomopathological examination of the gallbladder revealed in macroscopy a gallbladder of 4,5x2x1,5cm, partially covered by smooth grayish-green serosa. On cutting the middle wall 0,2 cm thick, 2 yellowish polyps of 0,2 and 0,1cm were identified, and, in addition, to the presence of 1 grayish nodule in the distal third of 0,9 cm. Microscopic evaluation revealed chronic cholecystitis with inflammatory polyps and ectopic pancreas in the distal wall of the gallbladder. Figure 1A-B

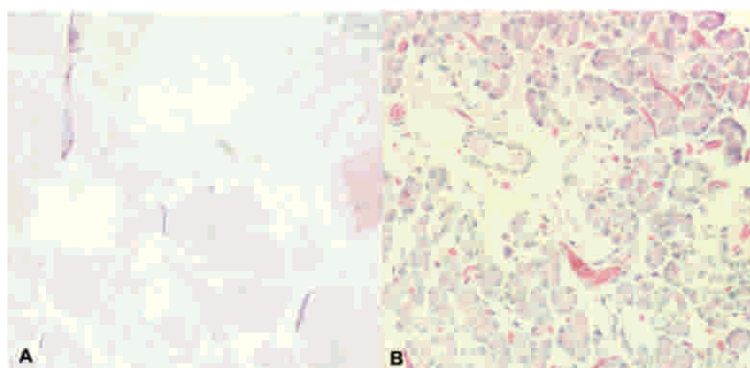


Figure 1: Histopathological evaluation of the gallbladder A: the wall with the presence of ectopic pancreatic tissue at the muscle layer level (Hematoxylin-Eosin staining x4). B: Ectopic pancreatic tissue (Hematoxylin-Eosin staining x40).



DISCUSSION

A choristoma (normal ectopic tissue located in an abnormal location) in the form of an ectopic or heterotopic pancreas is an embryological abnormality defined as pancreatic tissue with an aberrant location without presenting anatomical, vascular or neural connection to the pancreas⁽¹⁾. The most common location of the ectopic pancreas in the upper digestive tract (stomach, duodenum, jejunum, or spleen)^(1,3); however, it is rarely found elsewhere such as the ileum, mesentery, lungs, gallbladder, liver, bile duct, bile ducts, Meckel's diverticulum, or mediastinum^(2,3). The first description of the ectopic pancreas in the gallbladder dates back to 1916, by Otschkin⁽¹⁾, and to date, approximately 40 cases have been described worldwide^(2,3).

The particular case of ectopic pancreatic tissue in the gallbladder is extremely rare and is usually diagnosed when performing the examination. Pathology of a gallbladder that was removed during cholecystectomy for symptomatic gallbladder disease⁽²⁾. Preoperative diagnosis is practically impossible and, in general, this condition is found incidentally during necropsies or laparotomies for other reasons^(1,2). During reviews carried out in other countries, the ectopic pancreas in the gallbladder had an incidence of less than 0.5%⁽³⁾.

Epidemiologically, the ectopic pancreas can present at any age, but it is frequent between the fourth and sixth decades of life, being more frequent in males (three to five times more); however, if the ectopic pancreas is found in the gallbladder, the patient is usually a woman, since statistically surgical gallbladder pathology is more common in women than men⁽¹⁾.

The most accepted theory of the formation of this ectopic tissue is the one that describes a separation during the rotation of the gastrointestinal tract in the embryonic period⁽¹⁾. However, other reviews indicate an alteration in the Notch signaling system, which leads to differentiation during the development of the endoderm of the foregut; however, no theory explains this alteration exactly⁽²⁾.

The symptomatology of the ectopic pancreas is not specific, which include upper abdominal pain, anorexia, postprandial vomiting and weight loss⁽³⁾; however, most cases are asymptomatic^(1,4,5). Other reviews indicate tumors with mass effect up to perforation, gastrointestinal bleeding, and abdominal distention, depending on location in the gastrointestinal tract⁽⁴⁾. These ectopic tissues can lead to the development of metaplasias or neoplasias that can affect the normal pancreas; however, the finding of these tissues still lacks clinical significance and requires an exhaustive pathological examination to establish the diagnosis^(1,6).

The classification of the ectopic pancreas was described by Von Heinrich and later modified by Gaspar Fuentes, in which he describes 4 types^(1,3): Type 1: the presence of pancreatic acini, ducts, and islet-like glands, Type 2: canalicular variant with ducts pancreatic, Type 3: exocrine pancreas with acinar tissue, not endocrine tissue. Type 4: Endocrine pancreas with islet cells, not exocrine tissue. The usual size is small and usually does not exceed 2 or 3 cm; likewise, it usually lodges in the peri-vesicular fatty tissue^(3,6). In other cases, they can simulate a polypoid lesion and vary from millimeters to 4 cm; 50% of the lesions originate in the gallbladder neck and are present in the submucosa^(1,2).

Being normal pancreatic tissue lodged in another location can be susceptible to pathologies typical of pancreatic tissue in a normal location, such as acute and chronic pancreatitis, formation of cystic lesions, pseudocysts, calcifications, pancreatic cancer, and endocrine tumors⁽¹⁾. Regarding diagnosis, even though it has already been mentioned that preoperative diagnosis is usually very difficult and is usually found incidentally when this pathology is found in an area of the digestive tract such as the stomach, duodenum, or small intestine, it is usually associated with digestive bleeding; Therefore, a fine-needle biopsy of the lesion by ultrasound endoscopy is a tool widely used by gastroenterologists to define the diagnosis and potential treatment⁽⁶⁾. In the present case, the ectopic pancreatic tissue was found in the gallbladder, which made the preoperative diagnosis difficult and was performed by pathological examination incidentally.





CONCLUSIONS

Ectopic pancreas in the gallbladder is a fairly rare and infrequent pathology, which presents a challenge for both clinical and surgical medical personnel. Due to the real malignant potential, that can represent, the diagnosis should not be a personnel and should be

considered as a differential diagnosis in the context of gallbladder polyps associated with upper gastrointestinal symptoms. Likewise, it requires meticulous work by the pathologist for an adequate evaluation of the surgical specimen.

Authorship contributions: The authors participated in the genesis of the idea, project design, data collection and interpretation, results analysis and manuscript preparation of this research work.

Conflicts of interest: The authors express that there are no conflicts of interest when writing the manuscript.

Funding sources: Financing

Received: December 06, 2021

Approved: February 09, 2022

Correspondence: Ronald Alberto Goicochea Arevalo

Address: Jiron Joaquin Bernal 595 – Dpto 701. Lince – Lima – Peru

Telephone number: 945 666 530

E-mail: ronald_goicochea@hotmail.com

REFERENCES

- Sharma SP, Sohail SK, Makkawi S, Abdalla E. Heterotopic pancreatic tissue in the gallbladder. *Saudi Med J*. 2018 Aug;39(8):834-837. Doi: [10.15537/smj.2018.8.22602](https://doi.org/10.15537/smj.2018.8.22602)
- Lee SW, Yun SP, Seo HI. Heterotopic pancreas of the gallbladder associated with segmental adenomyomatosis of the gallbladder. *J Korean Surg Soc*. 2013 May;84(5):309-11. Doi: [10.4174/jkss.2013.84.5.309](https://doi.org/10.4174/jkss.2013.84.5.309)
- Koukourakis IM, Perente Memet MS, Kouroupi M, Simopoulos K. Ectopic Pancreatic Tissue Adherent to the External Gallbladder Wall. *Case Rep Gastroenterol*. 2018 Apr 24;12(1):170-175. Doi: <https://doi.org/10.1159/000488445>
- Li J, Huang H, Huo S, Liu Y, Xu G, Gao H, Zhang K, Liu T. Ectopic pancreatic tissue in the wall of the small intestine: Two rare case reports. *Medicine (Baltimore)*. 2017 Sep;96(35):e7986. Doi: [10.1097/MD.0000000000007986](https://doi.org/10.1097/MD.0000000000007986)
- Xiang S, Zhang F, Xu G. Ectopic pancreas in the ileum: An unusual condition and our experience. *Medicine (Baltimore)*. 2019 Nov;98(44):e17691. Doi: [10.1097/MD.00000000000017691](https://doi.org/10.1097/MD.00000000000017691)
- Attwell, A., Sams, S., & Fukami, N. (2014). Induction of acute ectopic pancreatitis by endoscopic ultrasound with fine-needle aspiration. *Clinical Gastroenterology and Hepatology*, 12(7), 1196-1198. Doi: [10.3748/wjg.v21.i8.2367](https://doi.org/10.3748/wjg.v21.i8.2367)

